

# UPMC REHAB GRAND ROUNDS

SPRING 2020



## Accreditation Statement

In support of improving patient care, the University of Pittsburgh is jointly accredited by the Accreditation Council for Continuing Medical Education (ACCME), the Accreditation Council for Pharmacy Education (ACPE), and the American Nurses Credentialing Center (ANCC), to provide continuing education for the health care team.

The University of Pittsburgh designates enduring material activity for a maximum of 0.5 *AMA PRA Category 1 Credit™*. Physicians should claim only the credit commensurate with the extent of their participation in the activity.

Other health care professionals will receive a certificate of attendance confirming the number of contact hours commensurate with the extent of participation in this activity.

## Disclosures

Drs. Webb and Moreta report no relationships with proprietary entities producing health care goods and services.

## Instructions

To take the CME evaluation and receive credit, please visit [UPMCPhysicianResources.com/Rehab](http://UPMCPhysicianResources.com/Rehab) and click on the course *Rehab Grand Rounds Spring 2020*.

Affiliated with the University of Pittsburgh School of Medicine, UPMC Presbyterian Shadyside is ranked among America's Best Hospitals by *U.S. News & World Report*.

# Current Concepts in Treating Hemiplegic Shoulder Pain



**KALI WEBB, DO**

*Assistant Professor  
Department of Physical Medicine and Rehabilitation  
University of Pittsburgh School of Medicine*



**MARISA MORETA, DO**

*Post Graduate Year 4  
Department of Physical Medicine and Rehabilitation  
University of Pittsburgh School of Medicine*

## Clinical Vignette

GM is a 65-year-old right-hand dominant male with a recent left middle cerebral artery stroke who presented to the UPMC inpatient rehabilitation unit with dense right hemiparesis and significant expressive and receptive aphasia. He had a 1.5 finger breadth inferior and anterior right shoulder subluxation, which was easily reducible with light pressure. He would complain of pain during occupational therapy sessions. He had mild spasticity throughout the right arm, graded 1 on the Modified Ashworth Scale. There were no changes to the color or texture of his skin, and there was no notable swelling. His therapists were concerned about the pain that he demonstrated and queried his physiatrists whether there was anything that could be done to help this patient.

## Definition of Poststroke Shoulder Pain

The four most common medical complications after stroke include hemiplegic shoulder pain (HSP), depression, falls, and urinary tract infections.<sup>1</sup> Studies have previously reported the frequency of HSP after stroke to be as high as 84%, with estimates varying depending on study methods.<sup>2,3</sup> A Swedish study performed in 2007 by *Lindgren et al.* found that in 416 patients with stroke, almost a third developed shoulder pain, most of whom reported moderate to severe pain.<sup>3</sup> The onset of shoulder pain in the stroke population is relatively rapid and can occur as soon as one week after stroke in up to 17% of patients.<sup>4</sup> However, others have reported that the peak onset and severity occurs around four months after stroke, which is notably outside of rehabilitation admission time frames and thus has important implications for screening and identification after discharge from inpatient rehabilitation (IPR).<sup>3,5</sup>

**Consults and Referrals:** For consults and referrals, please call UPMC's 24-hour physician OnDemand service at 1-866-884-8579.

**UPMC**  
LIFE CHANGING MEDICINE

Risk factors for the development of HSP are multifactorial and are summarized below in Box 1. The most notable predictor of developing HSP is the loss of motor function, with increased severity of motor impairment being more highly associated with the development of HSP.<sup>3</sup>

Poststroke shoulder pain not only hinders rehabilitation but also contributes to a longer hospital length of stay and decreased ability to return home, and is associated with depression and decreased quality of life.<sup>6-8</sup>

#### Box 1. Risk Factors for the Development of Shoulder Pain After Stroke<sup>6,9</sup>

- Loss of motor control
- Higher NIH Stroke Scale
- Decreased ROM with abduction and external rotation of shoulder
- History of shoulder pain
- Spasticity
- Decreased proprioception
- Decreased sensitivity to light touch
- Left-sided weakness
- Diabetes mellitus

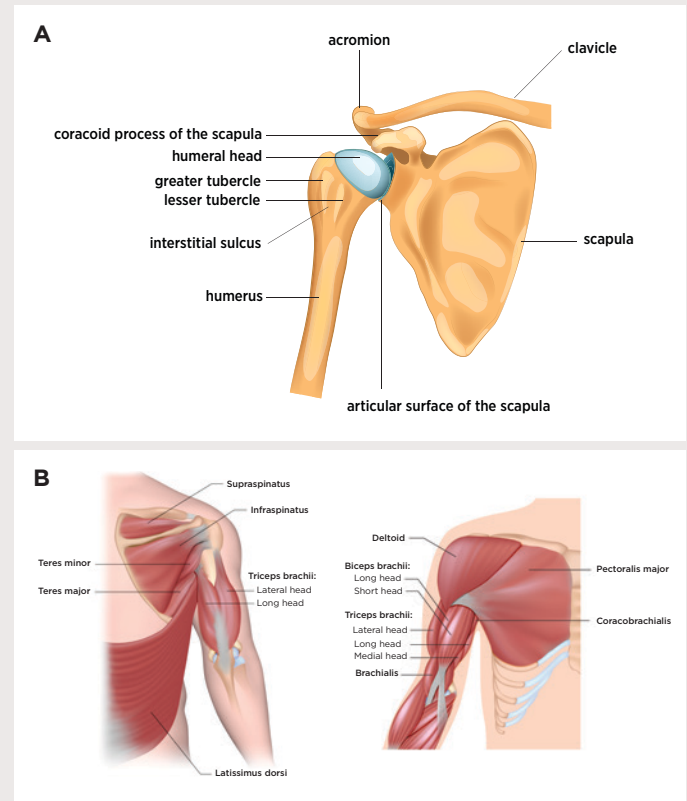
Abbreviations: NIH = National Institutes of Health, ROM = range of motion

### Shoulder Anatomy

The human shoulder is a complex ball-and-socket joint that allows multidirectional reach. Only 25% of the humeral head meets the glenoid, and the only true joint that directly connects the arm to the trunk is the sternoclavicular joint. Thus, both static and dynamic stabilizers are required to maintain joint stability (Image 1). The glenohumeral ligaments serve as the primary static stabilizers and include the superior, middle, and inferior glenohumeral ligaments. The primary dynamic stabilizers are the rotator cuff and deltoid muscles.

The glenohumeral joint derives passive support from the cartilaginous labrum, glenohumeral ligaments, and joint capsule. The position of the scapula is primarily controlled by the trapezius, serratus anterior, and latissimus dorsi. The subscapularis rotates the humerus internally, whereas the infraspinatus and teres minor are external rotators. Abduction is primarily achieved by the deltoid and is aided by the

supraspinatus. The rotator cuff muscles compress the humeral head in the glenoid fossa, thereby stabilizing the joint and providing a counterbalance to opposing forces on the humerus.



**Image 1.** Static (A) and Dynamic (B) stabilizers and muscles of the shoulder.

Overhead activity requires simultaneous abduction by the deltoid and external rotation by the infraspinatus. Movements in a single anatomic plane, such as abduction, can only be accomplished with a predictable ratio of movement known as scapulohumeral rhythm. Impairment of rotator cuff action can lead to superior subluxation of the humeral head, predisposing to impingement of the supraspinatus between the greater tubercle of the humerus and the acromion.<sup>6</sup>

### Pathophysiology and Differential Diagnosis

Common pathologies of HSP include neurologic and mechanical factors that are summarized in Box 2.

**Box 2.** Underlying Pathologies Associated with HSP<sup>6,9</sup>**Neurological Factors**

- Spasticity
- CRPS
- Poststroke central pain or hypersensitivity
- Peripheral nerve/brachial plexus injuries

**Mechanical Factors**

- Rotator cuff dysfunction
- Adhesive capsulitis
- Tendinopathy
- Impingement syndrome
- Contracture
- Bursitis
- Glenohumeral subluxation
- Myofascial pain
- Arthritis
- Scapular dyskinesia

Abbreviation: CRPS = Complex Regional Pain Syndrome

**Glenohumeral Subluxation**

Glenohumeral subluxation refers to the displacement of the humeral head in relation to the glenoid, and it represents a common source of mechanical pain in HSP. Clinically, a gap is appreciated between the humeral head and the acromion, which can be measured with calipers, radiography, or ultrasonography, but is commonly described by finger breadths.

During the early stages following stroke, the muscles in the hemiplegic arm are usually flaccid, thereby impairing joint stability and predisposing the shoulder to traction-type injury. Without active motor control there is a lack of dynamic stability, and articular tissues can become distended. This is hypothesized to contribute to ischemia in the tendons of the supraspinatus and long head of the biceps. Downward displacement of the humerus most commonly occurs during the flaccid stage, whereas during the spastic stage, anterior or posterior displacement or internal rotation can occur.<sup>6</sup> While the association between shoulder subluxation and HSP remains controversial, there is enough evidence to suggest that it may be a contributing factor. For example, a study performed by *Paci et al.* in 2007 looking at 107 hemiplegic patients found that those with shoulder subluxation had significantly greater pain at admission, discharge, and 30-day follow-up assessments.<sup>10</sup>

**Scapular Dyskinesia**

Scapulohumeral rhythm is often disrupted after stroke due to the combination of impaired strength, increased tone, and lack of smooth pursuit of the humerus and scapula, all acting together to put patients at increased risk of HSP.<sup>11</sup> Previous studies have shown that HSP survivors demonstrate aberrant recruitment of the scapula stabilizing muscles, such as the infraspinatus, serratus anterior, and inferior trapezius.<sup>12</sup> Clinically, patients with scapular dyskinesia will demonstrate impaired shoulder control with variability of scapular movement.

**Spasticity and Contractures**

Studies have reported that 85% of patients with spastic hemiplegia experienced pain compared to 18% of those with flaccid hemiplegia.<sup>13</sup> Of note, those with reduced external rotation appear to be at higher risk of experiencing pain.<sup>6</sup> Due to the decreased range of motion associated with spasticity, it can result in contractures of the shoulder if left untreated. Contractures can be independently painful, though pain also can be due to spasticity from the stretching and tension on the muscles.<sup>14</sup> Because spasticity and contractures exist on a continuum, they both can ultimately result in HSP.

**Impingement Syndrome and Rotator Cuff Injury**

Impingement syndrome is often thought of as an injury to the supraspinatus muscle or tendon that results from repetitive compression between the inferior border of the acromion and the greater tuberosity of the humerus. Although not extensively studied as a cause for HSP, one cross-sectional study has found that half of those with chronic HSP have evidence of impingement syndrome.<sup>15</sup> Additionally, improper resting positioning of the arm in bed or a chair or improper functional positioning during transferring may put the patient at an increased risk of developing impingement syndrome. Of note, impingement syndrome and rotator cuff injuries are common in the general population and tend to increase with age.

**Bicipital Tendinopathy**

Tendinosis of the biceps tendon, which is believed to occur more in stroke patients who suffer from spasticity or movement synergies of elbow flexion or forearm supination, has a prevalence of 7% to 54% in those with HSP.<sup>16,17</sup> Clinically, tendinosis is suspected when there is tenderness to palpation at the bicipital groove where the long head of the biceps lays at the anterior shoulder. Physical examination maneuvers can be helpful, such as the Yergason test which provokes pain at the anterior

shoulder with resisted forearm supination. However, the use of this provocative maneuver is limited if the patient has significant weakness. Injection of an anesthetic agent at the point that is most painful over the bicipital groove is diagnostic if it relieves symptoms.

### Adhesive Capsulitis

Adhesive capsulitis is defined as shortening and thickening of the glenohumeral joint capsule along with adhesions of the capsule and is characterized by shoulder pain with gradual loss of external rotation, which is a key physical exam component. MRI findings have shown increased thickening and contrast enhancement of synovial membrane compared to pain-free controls, supporting an association between HSP and adhesive capsulitis.<sup>18</sup> However, adhesive changes also have been found using arthrography in the contralateral shoulders of 30% of stroke survivors, indicating that while adhesive capsulitis may be contributing to HSP in a patient, it may not be the only factor involved.<sup>19</sup>

### Complex Regional Pain Syndrome

Complex Regional Pain Syndrome (CRPS) after stroke, also referred to as shoulder-hand syndrome, follows central nervous system (CNS) injury rather than damage to a peripheral nerve, which is related to CRPS type II.

#### Box 3. Diagnostic Criteria for Central Poststroke Pain (CPSP)<sup>9</sup>

##### Mandatory Criteria

- Pain within an area of the body corresponding to the lesion of the CNS
- Onset of pain at or soon after stroke
- Confirmation of a CNS lesion by imaging or negative or positive sensory signs confined to the area of the body corresponding to the lesion
- Other causes of pain, such as nociceptive or peripheral neuropathic pain, are excluded or considered highly unlikely

##### Supportive Criteria

- No primary relation to movement, inflammation, or other local tissue damage
- Descriptors such as burning, painful cold, electric shocks, aching, pressing, stinging, and pins and needles, although all pain descriptors can apply
- Allodynia or dysesthesia to touch or cold

Overall, CRPS describes an array of painful conditions that are characterized by a continuous spontaneous or evoked regional pain that is disproportionate in time or degree to the expected pain presentation. The pain is not in a specific nerve territory or dermatome but is more distal and associated with abnormal sensory, motor, and trophic findings (edema, color, and temperature changes).<sup>20</sup> The exact cause is unknown, but hypotheses include sympathetic sprouting of the sensory ganglia and peripheral nerves causing microcirculatory dysfunction.<sup>21</sup>

The prevalence of CRPS type I in hemiplegia has been reported in the literature to be as high as 23%.<sup>13</sup> Risk factors for CRPS type I include motor impairment and trauma related to altered shoulder biomechanics. The diagnosis of CRPS is based on clinical examination and can be aided by standardized criteria known as the Budapest criteria.

### Central Poststroke Pain

Central poststroke pain (CPSP), which was formerly known as thalamic pain syndrome, is a neuropathic pain syndrome that can arise from a stroke localized to the spino-thalamo-cortical pathway. It is thought that those with CPSP have multiple lesions that can be visualized on MRI.<sup>22,23</sup> The pain may be due to the lesion, although it also might be caused by neuroplasticity that occurs after the stroke. Typically, the pain arises gradually within the first month after stroke. If pain arises more than 12 months after stroke, it might be reasonable to look for another cause. The clinical presentation of CPSP can be variable, and an algorithm to improve the diagnosis has been proposed (Box 3), although diagnostic criteria for CPSP have not been established.

### Osteoarthritis

Osteoarthritis commonly presents as a gradual increase in pain, stiffness, and decreased motion of the affected joint. Risk factors for glenohumeral osteoarthritis may include genetic susceptibility, nutrition, osteoporosis, joint injury, and body weight. It has been reported that approximately 91% of patients with long-standing rheumatoid arthritis ultimately develop shoulder involvement.<sup>24</sup> In a group of 152 patients with a mean age of 70.6 years, 52 reported shoulder pain but only five were considered to have osteoarthritis as the underlying etiology.<sup>7</sup>

## Examination and Diagnosis

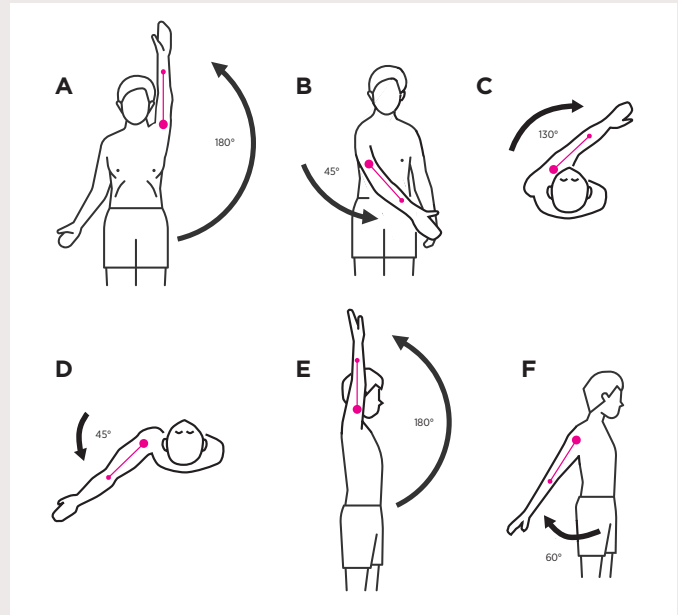
### History and Physical

It is important to elicit information on preexisting shoulder pain, limited functional use of the arm, prior trauma, and surgeries. The patient should demonstrate how much active range of motion (AROM) they are able to achieve, and then the examiner should assess full passive range of motion (PROM). Pain is most often the limiting factor in AROM, followed by weakness. If there is reduced PROM, contracture or anatomic block should be suspected. Normal range of motion of the shoulder varies from person to person. A general guideline is provided in Table 1 and Figure 1.

**Table 1.** Normal Range of Motion of the Shoulder

<b>Flexion</b>	0 – 180°
<b>Extension</b>	0 – 60°
<b>Adduction</b>	0 – 50°
<b>Abduction</b>	0 – 150°
<b>Internal Rotation</b>	0 – 70°
<b>External Rotation</b>	0 – 90°

There are special tests that can be used in the diagnosis of HSP. Physical exam maneuvers offer greater value when multiple tests are positive or when the examiner is able to note differences on the affected side as compared to the unaffected side. A study performed by *Rajaratnam et al.* found that HSP could successfully be diagnosed clinically using three special tests: Neer test; hand-behind-neck maneuver; and external rotation at the shoulder joint with a difference of greater than 10 degrees passively being significant. If the patient had a concomitant report of at least moderate pain at rest, the sensitivity and positive predictive value for HSP was 96.7%<sup>25</sup> (Table 2).



**Figure 1.** Shoulder Range of Motion **A.** Abduction (bringing up the arm sideways); **B.** Adduction; **C.** Horizontal Flexion (swinging the arm horizontally); **D.** Horizontal Extension; **E.** Vertical Flexion; **F.** Vertical Extension.

**Table 2.** Three Physical Exam Maneuvers That Help Predict HSP When Used Together<sup>25</sup>

<b>Maneuver</b>	<b>Description of Test</b>
<b>Neer Test</b>	Limit patients' scapular rotation with one hand while using the other hand to internally rotate the affected arm in a passive mode through elevation in the scapular plane. Shoulder pain during this test is suggestive of subacromial impingement
<b>Hand-behind-neck (HBN)</b>	External rotation and abduction cause moderate or greater shoulder pain
<b>External Rotation</b>	There is a > 10° difference in ROM between shoulders during passive external rotation



## Treatment Options

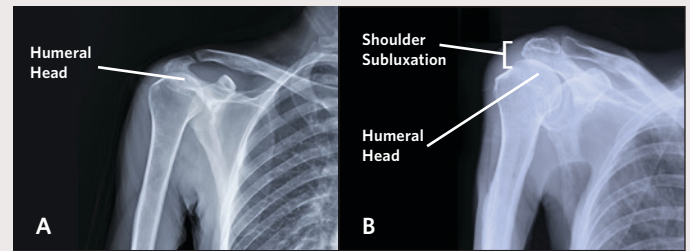
### Prevention

During the flaccid stage, the shoulder is especially at risk of injury due to laxity surrounding the shoulder capsule (Image 2). For this reason, it is important for the patient and caregivers to be educated on proper handling and positioning of the arm. Initial goals include preventing the application of excessive stress to the shoulder by reducing the effect of gravity with slings or lap trays in wheelchairs, and by reducing traction on the arm during transfers.<sup>6</sup> There is no clear guideline regarding which method best reduces strain on the shoulder. However, some have suggested placing the arm with shoulder protracted, arm forward, wrist neutral and slightly supinated, and fingers extended.<sup>26</sup> Additionally, it is recommended that the affected limb is positioned in a way that counteracts the effects of muscle spasticity.

### Positioning Aids

The Kinesio® taping (KT) (Image 3) was developed by Kenzo Kase in the 1970s and has gradually become widely used as a clinical intervention in the treatment of musculoskeletal disorders. The product is a thin, elastic, cotton tape applied to the skin, which can stretch to up to 140% of its original length. The tape can reduce mechanical retention and restriction of movement. Prescribed wear time for one application is usually three to four days. Taping perpendicular to a muscle inhibits activity, and taping parallel to a muscle promotes activity.<sup>25</sup> A double-blind, randomized, placebo-controlled study performed by *Huang et al.* in 2017 involving 21 patients found that HSP patients experienced greater reductions in pain and improvements in shoulder flexion and external and internal rotation after three weeks of Kinesio taping when compared with sham taping.<sup>27</sup>

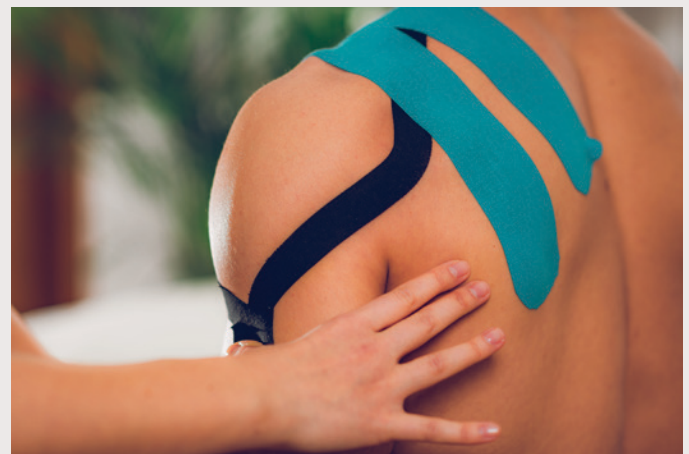Slings also can be protective and helpful for ambulation in the stroke patient, as they may help promote efficiency and gait speed. The GivMohr® Sling holds the arm in a functional position, with the elbow in 30 degrees of flexion and the wrist in 30 degrees of extension. Subluxation cuffs are another method to minimize or prevent subluxation and support the arm proximally while giving more freedom of movement distally (Image 4). Overall, shoulder orthoses are generally well tolerated and comfortable to wear. A systematic review by *Nadler and Pauls* in 2017, which included 186 participants, demonstrated that shoulder orthoses in stroke patients had been shown to reduce vertical subluxation, however, the positional benefits are not maintained when removed.<sup>28</sup>



**Image 2. Shoulder Subluxation as a Result of Flaccid Muscle Tone**

A) Normal shoulder. The humeral head is maintained in the glenoid fossa by the supraspinatus muscle. B) Shoulder subluxation. The supraspinatus muscle is flaccid during the initial phase of hemiplegia. The weight of the unsupported arm can cause the humeral head to sublux downward in the glenoid fossa.

Arm troughs and lap trays also are useful to support the limb, prevent shoulder subluxation, and prevent traumatic injury. Arm troughs or lap boards are often preferred positioning methods as they do not restrict the use of the limb and the humerus is more naturally approximated into the glenoid fossa.<sup>29</sup>



**Image 3. Kinesio Taping**

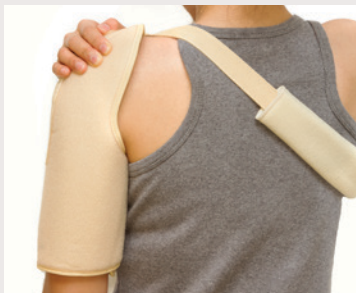### Range of Motion

Passive range of motion (PROM) should be initiated as soon as the patient is medically stable. However, care should be taken during passive abduction of the arm to minimize rotator cuff injury. For example, progressive range of motion programs that use overhead pulleys should be avoided due to the risk of injury.<sup>9</sup> Robot-assisted PROM devices have shown some success in the treatment of HSP. *Kim et al.* evaluated robot-assisted shoulder rehabilitation therapy for HSP and found that when this therapy was administered for 30 minutes daily, five times per week for four weeks, patients had significantly less pain and increased ability to abduct the shoulder passively.<sup>30</sup> While physical therapy regimens are individualized per patient, other common

exercises will include scapular stabilization, strengthening, and neuromuscular re-education, as well as gentle stretching. Other conservative modalities that can be used to help symptomatically include heat and cold therapy.

### Electrical Stimulation

Transcutaneous electrical nerve stimulation (TENS) is a modality that provides an external electrical stimulus to the affected limb to decrease pain through the gate control theory of pain. Additionally, at higher intensities, the electrical impulses can also activate muscles to assist in the maintenance of muscle bulk to prevent atrophy. There is some evidence that high-intensity TENS may reduce HSP in comparison to low-intensity TENS or placebo.<sup>31</sup> A study by Zhou *et al.* published in 2018 compared neuromuscular electrical stimulation (NMES) to TENS in 90 patients with HSP, administering 20 sessions over four weeks targeting the supraspinatus and deltoid muscles. The authors found that while both NMES and TENS significantly reduced pain, NMES was superior to TENS in maintaining long-term analgesia.<sup>32</sup>



**Image 4.** Subluxation Cuff

Functional electrical stimulation (FES), which is a technique that uses low-energy electrical pulses to artificially generate body movements via electrodes placed on the skin over the muscles of interest, has been shown in several studies to reduce HSP and shoulder subluxation.<sup>33</sup> FES usually is directed at the supraspinatus or posterior deltoid muscles because of their roles in maintaining dynamic shoulder stability.

There is evidence supporting percutaneous intramuscular peripheral nerve stimulation (PNS) to improve shoulder pain. Intramuscular electrical stimulation (IES), which involves stimulation directly to the targeted muscles via a percutaneous electrode, has the advantage of direct stimulation and reduced pain, but is not yet widely available.<sup>34</sup> Intramuscular electrodes are applied via needle between the middle and posterior deltoid motor points, and then the area is stimulated for six hours per day for three weeks. Compared to PT only, patients maintained

improvement of pain for 12 weeks after the intervention, whereas in the PT-only group, pain worsened six to 12 weeks after intervention.<sup>35,36</sup> There was a statistically greater improvement in baseline shoulder pain at 12 weeks after PNS, indicating that biomechanical improvements alone do not account for pain reduction, but other factors such as reducing the impact of central sensitization may be involved.<sup>36</sup> There also is data on implantable single lead axillary PNS providing benefit in pain reduction up to two years after implantation.<sup>37</sup>

### Other Modalities

Mirror therapy also can be used to treat HSP if the etiology is felt to be related to CRPS. In mirror therapy, a mirror is placed beside the unaffected limb, blocking the view of the affected limb and creating an illusion of two limbs as if they are both functioning normally (Image 5). The concept behind this process is for the movement of one limb to be perceived as movement from the other limb, and this is thought to induce neuroplastic changes by increasing excitability of the ipsilateral motor cortex which projects to the paretic limb.<sup>38</sup> Mirror therapy has been demonstrated in small randomized controlled studies to be a helpful adjunct in the treatment of CRPS in pain perception and improved motor function of the upper limb.<sup>39</sup>

Mental practice, or guided imagery, involves cognitively rehearsing a specific task by repetitively imagining oneself performing the precise movements involved in the task in the absence of performing the physical movement. This technique is another useful adjunct in the treatment of CRPS and may promote neuroplastic changes without causing the affected individual any discomfort since movement of the affected limb can cause pain.<sup>40</sup>



**Image 5.** Mirror Therapy

Other modalities that have shown some promise in the treatment of HSP include electromyography (EMG) biofeedback and relaxation exercises. A randomized, crossover trial had 20 patients with HSP perform either EMG biofeedback (30 minutes daily for five days) or relaxation exercises (30 minutes daily for two days) and found that both groups demonstrated increased range of motion, increased muscle tone, and a 50% to 60% reduction in pain.<sup>6</sup>

## Pharmacotherapy

First-line treatment can include oral analgesics such as acetaminophen and nonsteroidal anti-inflammatory drugs (NSAIDs), which are both commonly used in the general population and in HSP. While there is limited data to directly support the use of NSAIDs and acetaminophen in the poststroke shoulder pain population, clinically many patients do experience some benefit.<sup>41</sup> Topical analgesics may be considered, such as diclofenac or lidocaine cream/patches, which can be applied to painful areas with limited systemic absorption and help to avoid some of the unwanted systemic effects of NSAIDs (e.g., antiplatelet effect, increased risk of gastric ulcers).

Gabapentin can be helpful in the treatment of neuropathic pain, and if ineffective or if the patient cannot tolerate side effects, pregabalin can be trialed. In a study performed by *Rahman and Uddin* in 2010, 70 poststroke patients with shoulder pain were randomized to pregabalin 100 mg twice daily plus therapeutic ultrasound for 10 minutes daily, or therapeutic ultrasound alone. After treatment for two weeks, the patients in the pregabalin group demonstrated statistically significant greater improvement in pain as measured on the VAS scale.<sup>42</sup>

Evidence to support amitriptyline in HSP with underlying CPSP dates to a study published in 1989 by *Leijon and Boivie* that examined the efficacy of amitriptyline (25 mg/day titrated up to 75 mg/day) in a double-blind, placebo-controlled, crossover study. Among 15 patients tested, improvement in pain was reported in one subject who received a placebo and 10 subjects treated with amitriptyline.<sup>43</sup> Although it enrolled only 15 patients, this was the first study to prove the efficacy of amitriptyline in the treatment of CPSP. Disadvantages include anticholinergic side effects such as dry mouth, urinary retention, somnolence, and confusion, especially in older stroke patients.

For patients who have emerging spasticity, medications such as baclofen, tizanidine, or dantrolene can be used. Focal spasticity may be more effectively treated with localized botulinum toxin injections. A Cochrane Review performed in 2011, which examined five randomized controlled trials, found that in

patients with shoulder pain and spasticity after hemiplegia, a single injection of botulinum toxin A was associated with a statistically significantly greater reduction in pain severity at three to six months compared to placebo. Significantly greater improvements in external shoulder rotation were noted at one month but not at three to six months. Muscles that were targeted in these studies include the subscapularis, pectoralis major, and biceps brachii.<sup>44</sup>

While there are no definitive treatments for CRPS, multiple potential treatments and modalities have been proposed and are geared toward a patient's prominent symptoms (Box 4). Additionally, there has been some recent data to support the use of oral corticosteroids in the treatment of HSP. In a trial by *Kalita et al.*, 60 patients were randomized to either prednisolone 40 mg or piroxicam 20 mg daily. The study found that at one month the prednisolone group experienced significant improvement as compared to piroxicam, while both drugs did show improvement in the Barthel Index score.<sup>45</sup> In another randomized trial by *Eun Young et al.* in 2016, 21 hemiplegic stroke patients were randomly assigned to receive either intravenous pamidronate or oral prednisolone. Both groups showed significant improvement in VAS pain scores at one- and four-week follow-ups, and improvements in finger and hand edema were observed in both groups, however with longer duration in the prednisolone group.<sup>46</sup>

### Box 4. Interventions for the Treatment of HSP Caused by CRPS<sup>47</sup>

#### Symptoms: sweating, trophic changes, coldness

- Sympathetic nerve block at stellate ganglion
- Mobilization, strengthening, desensitization, and functional restoration

#### Symptoms: hyperesthesia, hyperalgesia, allodynia

- Desensitization
- Antiepileptic medications (gabapentin, carbamazepine)
- Tricyclic antidepressants
- NMDA receptor antagonists

#### Symptoms: impaired tactile discrimination, referred sensation, dystonia

- Edema control, mobilization, strengthening
- Mirror therapy
- Mental imagery

#### Symptoms: warmth, erythema, edema, pain

- Oral corticosteroids
- Nonsteroidal anti-inflammatory drugs
- Biofeedback

Abbreviation: NMDA = N-methyl-D-aspartate.



## Injection Therapy

### Intra-articular injections

Intra-articular corticosteroid injections are commonly used for glenohumeral or acromioclavicular arthritis and sometimes for the pain associated with adhesive capsulitis, either using landmark guidance or ultrasound. With repeated injections, corticosteroids can be harmful to cartilage and tendons and can speed degeneration, as well as cause fat atrophy and hypopigmentation.<sup>48,49</sup> In the setting of adhesive capsulitis, large volume injections can help with capsular distention to improve mobility.

Platelet-rich plasma (PRP) has received attention recently, especially for use in tendinopathy. It has gained more attention for the treatment of osteoarthritis of the knee, but there are no studies currently to support its use for glenohumeral osteoarthritis or HSP.

Hyaluronic acid injections are often used for knee osteoarthritis, and, similarly to PRP, data has been extrapolated for use in the shoulder; however, the benefit for shoulder pain remains controversial. *Jang et al.* evaluated 31 patients randomized into steroid versus hyaluronic acid intra-articular shoulder injections for relief of hemiplegic shoulder pain, and there was no statistical difference between the groups with range of movement or pain after eight weeks; however, there was an improvement in nocturnal pain in the hyaluronic acid group.<sup>50</sup>

### Nerve blocks

Suprascapular nerve blocks may be considered for shoulder pain. It is hypothesized that afferent fibers of the suprascapular nerve may become sensitized or entrapped due to chronic pain or injury, contributing to the experience of shoulder pain after stroke.<sup>51</sup> Suprascapular nerve blocks showed similar, if not better, efficacy in improving pain and range of motion using bupivacaine as compared to glenohumeral corticosteroid injections, without the side effects seen with repeated steroid injections.<sup>52</sup> When combined with physical therapy, suprascapular nerve blocks are associated with further improvements in range of motion and pain when compared to injection or therapy alone.<sup>48</sup>

### Stellate ganglion blocks

Stellate ganglion blocks are historically done with landmark or fluoroscopy guidance, but both methods are associated with risk of injury to the thyroid gland, blood vessels, and the esophagus due to limitations of surrounding soft tissue visualization.

Ultrasound guidance allows for active visualization of such structures and spread of anesthetic, and thus may offer a safety advantage. When comparing landmark guidance to ultrasound guidance, the ultrasound group required a smaller volume of anesthetic to achieve Horner's syndrome more quickly with improved pain relief. Both groups offered improvement to hand swelling, though there are likely multiple factors contributing to hand swelling after stroke outside of vasomotor autonomic dysfunction, like decreased lymphatic and venous drainage from decreased muscle tone and activity after stroke.<sup>21</sup>

## Complementary Treatment

Acupuncture is thought to help release neurohormones to relieve pain by halting pain signals in nerves and by increasing energy flow throughout the body. The exact mechanism remains unclear.<sup>6,53</sup> There are studies showing that acupuncture is an effective adjuvant therapy in HSP due to CRPS or subluxation when used in combination with an exercise program.<sup>53</sup>

## Surgery

Surgical intervention is reserved for last resort after other management modalities have failed. These procedures can include manipulation under anesthesia for adhesive capsulitis, muscle and tendon lengthening procedures for contractures, and spinal cord stimulator placement for CRPS. Rotator cuff repair is often not pursued in hemiplegic shoulder pain unless function is negatively impacted due to an acute traumatic rupture.<sup>6</sup>

## Clinical Vignette Outcome

Multiple modalities were employed to assist GM with his intermittent shoulder pain. A shoulder x-ray showed a subluxation but no fractures and only mild glenohumeral and acromioclavicular osteoarthritis. His spasticity was quite mild and was not felt to be contributory. He improved with proper wheelchair positioning using an arm trough and lateral supports to maintain trunk posture. He also responded to Kinesio taping to reduce the degree of subluxation. Additionally, the patient used a GivMohr Sling during ambulation to maintain his right shoulder and arm in a better position with less risk of injury. Electrical stimulation was tried, but no notable response was felt over the posterior deltoid, infraspinatus, or supraspinatus; this modality was discontinued. Though he did not verbally express allodynia, he did demonstrate grimacing on light touch of his right lower extremity. Gabapentin was initiated and eliminated any further complaint of right shoulder pain during therapy sessions. Thus, central poststroke pain was thought to be GM's most significant contributing factor to his shoulder pain experience.

## References

- McLean DE. Medical Complications Experienced by a Cohort of Stroke Survivors During Inpatient, Tertiary-Level Stroke Rehabilitation. *Arch Phys Med Rehabil*. 2004; 85(3): 466-469.
- Najenson T, Yacubovich E, Pikielni SS. Rotator Cuff Injury in Shoulder Joints of Hemiplegic Patients. *Scand J Rehabil Med*. 1971; 3(3): 131-137.
- Lindgren I, Jonsson AC, Norrving B, Lindgren A. Shoulder Pain After Stroke: A Prospective Population-Based Study. *Stroke*. 2007; 38(2): 343-348.
- Ratnasabapathy Y, Broad J, Baskett J, Pledger M, Marshall J, Bonita R. Shoulder Pain in People With a Stroke: A Population-Based Study. *Clin Rehabil*. 2003; 17(3): 304-311.
- Adey-Wakeling Z, Arima H, Crotty M, Leyden J, Kleinig T, Anderson CS, Newbury J, Collaborative SS. Incidence and Associations of Hemiplegic Shoulder Pain Poststroke: Prospective Population-Based Study. *Arch Phys Med Rehabil*. 2015; 96(2): 241-247 e241.
- Vasudevan JM, Browne BJ. Hemiplegic Shoulder Pain: An Approach to Diagnosis and Management. *Phys Med Rehabil Clin N Am*. 2014; 25(2): 411-437.
- Gamble GE, Barberan E, Laasch HU, Bowsher D, Tyrrell PJ, Jones AK. Poststroke Shoulder Pain: A Prospective Study of the Association and Risk Factors in 152 Patients From a Consecutive Cohort of 205 Patients Presenting With Stroke. *Eur J Pain*. 2002; 6(6): 467-474.
- Adey-Wakeling Z, Liu E, Crotty M, Leyden J, Kleinig T, Anderson CS, Newbury J. Hemiplegic Shoulder Pain Reduces Quality of Life After Acute Stroke: A Prospective Population-Based Study. *Am J Phys Med Rehabil*. 2016; 95(10): 758-763.
- Wilson RD, Chae J. Hemiplegic Shoulder Pain. *Phys Med Rehabil Clin N Am*. 2015; 26(4): 641-655.
- Paci M, Nannetti L, Taiti P, Baccini M, Rinaldi L. Shoulder Subluxation After Stroke: Relationships With Pain and Motor Recovery. *Physiother Res Int*. 2007; 12(2): 95-104.
- Niessen M, Janssen T, Meskers C, Koppe P, Konijnenbelt M, Veeger D. Kinematics of the Contralateral and Ipsilateral Shoulder: A Possible Relationship With Post-Stroke Shoulder Pain. *J Rehabil Med*. 2008; 40(6): 482-486.
- De Baets L, Jaspers E, Janssens L, Van Deun S. Characteristics of Neuromuscular Control of the Scapula After Stroke: A First Exploration. *Front Hum Neurosci*. 2014; 8: 933.
- Van Ouwenaller C, Laplace PM, Chantraine A. Painful Shoulder in Hemiplegia. *Arch Phys Med Rehabil*. 1986; 67(1): 23-26.
- Braun RM, West F, Mooney V, Nickel VL, Roper B, Caldwell C. Surgical Treatment of the Painful Shoulder Contracture in the Stroke Patient. *J Bone Joint Surg Am*. 1971; 53(7): 1307-1312.
- Joynt RL. The Source of Shoulder Pain in Hemiplegia. *Arch Phys Med Rehabil*. 1992; 73(5): 409-413.
- Shah RR, Haghighpanah S, Elovic EP, Flanagan SR, Behnegar A, Nguyen V, Page SJ, Fang ZP, Chae J. MRI Findings in the Painful Poststroke Shoulder. *Stroke*. 2008; 39(6): 1808-1813.
- Dromerick AW, Edwards DF, Kumar A. Hemiplegic Shoulder Pain Syndrome: Frequency and Characteristics During Inpatient Stroke Rehabilitation. *Arch Phys Med Rehabil*. 2008; 89(8): 1589-1593.
- Tavora DG, Gama RL, Bomfim RC, Nakayama M, Silva CE. MRI Findings in the Painful Hemiplegic Shoulder. *Clin Radiol*. 2010; 65(10): 789-794.
- Hakuno A, Sashika H, Ohkawa T, Itoh R. Arthrographic Findings in Hemiplegic Shoulders. *Arch Phys Med Rehabil*. 1984; 65(11): 706-711.
- Harden RN, Bruehl S, Stanton-Hicks M, Wilson PR. Proposed New Diagnostic Criteria for Complex Regional Pain Syndrome. *Pain Med*. 2007; 8(4): 326-331.
- Yoo SD, Jung SS, Kim HS, Yun DH, Kim DH, Chon J, Hong DW. Efficacy of Ultrasonography Guided Stellate Ganglion Blockade in the Stroke Patients With Complex Regional Pain Syndrome. *Ann Rehabil Med*. 2012; 36(5): 633-639.
- Hong JH, Bai DS, Jeong JY, Choi BY, Chang CH, Kim SH, Ahn SH, Jang SH. Injury of the Spino-thalamo-cortical Pathway Is Necessary for Central Post-stroke Pain. *Eur Neurol*. 2010; 64(3): 163-168.
- Bowsher D, Leijon G, Thuomas KA. Central Poststroke Pain: Correlation of MRI With Clinical Pain Characteristics and Sensory Abnormalities. *Neurology*. 1998; 51(5): 1352-1358.
- Jain NB, Higgins LD, Guller U, Pietrobon R, Katz JN. Trends in the Epidemiology of Total Shoulder Arthroplasty in the United States From 1990-2000. *Arthritis Rheum*. 2006; 55(4): 591-597.
- Rajaratnam BS, Venketasubramanian N, Kumar PV, Goh JC, Chan YH. Predictability of Simple Clinical Tests to Identify Shoulder Pain After Stroke. *Arch Phys Med Rehabil*. 2007; 88(8): 1016-1021.
- Carr EK, Kenney FD. Positioning of the Stroke Patient: A Review of the Literature. *Int J Nurs Stud*. 1992; 29(4): 355-369.
- Huang YC, Chang KH, Liou TH, Cheng CW, Lin LF, Huang SW. Effects of Kinesio Taping for Stroke Patients With Hemiplegic Shoulder Pain: A Double-blind, Randomized, Placebo-controlled Study. *J Rehabil Med*. 2017; 49(3): 208-215.
- Nadler M, Pauls M. Shoulder Orthoses for the Prevention and Reduction of Hemiplegic Shoulder Pain and Subluxation: Systematic Review. *Clin Rehabil*. 2017; 31(4): 444-453.
- Cifu DX. Braddom's Physical Medicine & Rehabilitation. Philadelphia, PA: Elsevier; 2016. xxiii, 1204 pages.
- Kim MS, Kim SH, Noh SE, Bang HJ, Lee KM. Robotic-Assisted Shoulder Rehabilitation Therapy Effectively Improved Poststroke Hemiplegic Shoulder Pain: A Randomized Controlled Trial. *Arch Phys Med Rehabil*. 2019; 100(6): 1015-1022.

31. Leandri M, Parodi CI, Corrieri N, Rigardo S. Comparison of TENS Treatments in Hemiplegic Shoulder Pain. *Scand J Rehabil Med*. 1990; 22(2): 69-71.
32. Zhou M, Li F, Lu W, Wu J, Pei S. Efficiency of Neuromuscular Electrical Stimulation and Transcutaneous Nerve Stimulation on Hemiplegic Shoulder Pain: A Randomized Controlled Trial. *Arch Phys Med Rehabil*. 2018; 99(9): 1730-1739.
33. Wang RY, Chan RC, Tsai MW. Functional Electrical Stimulation on Chronic and Acute Hemiplegic Shoulder Subluxation. *Am J Phys Med Rehabil*. 2000; 79(4): 385-390; quiz 391-394.
34. Chae J, Yu DT, Walker ME, Kirsteins A, Elovic EP, Flanagan SR, Harvey RL, Zorowitz RD, Frost FS, Grill JH, Fang ZP. Intramuscular Electrical Stimulation for Hemiplegic Shoulder Pain: A 12-Month Follow-Up of a Multiple-Center, Randomized Clinical Trial. *Am J Phys Med Rehabil*. 2005; 84(11): 832-842.
35. Wilson RD, Gunzler DD, Bennett ME, Chae J. Peripheral Nerve Stimulation Compared With Usual Care for Pain Relief of Hemiplegic Shoulder Pain: A Randomized Controlled Trial. *Am J Phys Med Rehabil*. 2014; 93(1): 17-28.
36. Wilson RD, Knutson JS, Bennett ME, Chae J. The Effect of Peripheral Nerve Stimulation on Shoulder Biomechanics: A Randomized Controlled Trial in Comparison to Physical Therapy. *Am J Phys Med Rehabil*. 2017; 96(3): 191-198.
37. Wilson RD, Bennett ME, Nguyen VQC, Bock WC, O'Dell MW, Watanabe TK, Amundson RH, Hoyen HA, Chae J. Fully Implantable Peripheral Nerve Stimulation for Hemiplegic Shoulder Pain: A Multi-Site Case Series With Two-Year Follow-Up. *Neuromodulation*. 2018; 21(3): 290-295.
38. Deconinck FJ, Smorenburg AR, Benham A, Ledebt A, Feltham MG, Savelsbergh GJ. Reflections on Mirror Therapy: A Systematic Review of the Effect of Mirror Visual Feedback on the Brain. *Neurorehabil Neural Repair*. 2015; 29(4): 349-361.
39. Pervane Vural S, Nakipoglu Yuzer GF, Sezgin Ozcan D, Demir Ozbudak S, Ozgirgin N. Effects of Mirror Therapy in Stroke Patients With Complex Regional Pain Syndrome Type 1: A Randomized Controlled Study. *Arch Phys Med Rehabil*. 2016; 97(4): 575-581.
40. Moseley GL. Graded Motor Imagery for Pathologic Pain: A Randomized Controlled Trial. *Neurology*. 2006; 67(12): 2129-2134.
41. Turner-Stokes L, Jackson D. Shoulder Pain After Stroke: A Review of the Evidence Base to Inform the Development of an Integrated Care Pathway. *Clin Rehabil*. 2002; 16(3): 276-298.
42. Rahman MS, Uddin MT. Comparative Efficacy of Pregabalin and Therapeutic Ultrasound Versus Therapeutic Ultrasound Alone on Patients With Post Stroke Shoulder Pain. *Mymensingh Med J*. 2014; 23(3): 456-460.
43. Leijon G, Boivie J. Central Post-Stroke Pain — A Controlled Trial of Amitriptyline and Carbamazepine. *Pain*. 1989; 36(1): 27-36.
44. Singh JA, Fitzgerald PM. Botulinum Toxin for Shoulder Pain. *Cochrane Database Syst Rev*. 2010(9): CD008271.
45. Kalita J, Vajpayee A, Misra UK. Comparison of Prednisolone With Piroxicam in Complex Regional Pain Syndrome Following Stroke: A Randomized Controlled Trial. *QJM*. 2006; 99(2): 89-95.
46. Eun Young H, Hyeyun K, Sang Hee I. Pamidronate Effect Compared With a Steroid on Complex Regional Pain Syndrome Type I: Pilot Randomised Trial. *Neth J Med*. 2016; 74(1): 30-35.
47. Chae J. Poststroke Complex Regional Pain Syndrome. *Top Stroke Rehabil*. 2010; 17(3): 151-162.
48. Chang KV, Hung CY, Wu WT, Han DS, Yang RS, Lin CP. Comparison of the Effectiveness of Suprascapular Nerve Block With Physical Therapy, Placebo, and Intra-Articular Injection in Management of Chronic Shoulder Pain: A Meta-Analysis of Randomized Controlled Trials. *Arch Phys Med Rehabil*. 2016; 97(8): 1366-1380.
49. Huang YC, Leong CP, Tso HH, Chen MJ, Liaw MY, Hsieh HC, Wang LY, Hsu CH. The Long-term Effects of Hyaluronic Acid on Hemiplegic Shoulder Pain and Injury in Stroke Patients: A Randomized Controlled Study. *Medicine (Baltimore)*. 2018; 97(35): e12078.
50. Jang MH, Lee CH, Shin YI, Kim SY, Huh SC. Effect of Intra-articular Hyaluronic Acid Injection on Hemiplegic Shoulder Pain After Stroke. *Ann Rehabil Med*. 2016; 40(5): 835-844.
51. Aydin T, Sen EI, Yardimci MY, Kesiktaş FN, Ones K, Paker N. Efficacy of Ultrasound-Guided Suprascapular Nerve Block Treatment in Patients With Painful Hemiplegic Shoulder. *Neurol Sci*. 2019; 40(5): 985-991.
52. Sencan S, Celenlioglu AE, Karadag-Saygi E, Midi I, Gunduz OH. Effects of Fluoroscopy-Guided Intraarticular Injection, Suprascapular Nerve Block, and Combination Therapy in Hemiplegic Shoulder Pain: A Prospective Double-Blind, Randomized Clinical Study. *Neurol Sci*. 2019; 40(5): 939-946.
53. Lee JA, Park SW, Hwang PW, Lim SM, Kook S, Choi KI, Kang KS. Acupuncture for Shoulder Pain After Stroke: A Systematic Review. *J Altern Complement Med*. 2012; 18(9): 818-823.

## UPMCPhysicianResources.com/Rehab



### ADDRESS CORRESPONDENCE TO:

#### Michael C. Munin, MD

Senior Editor and Vice Chairman  
Strategic Planning and Program Development  
Department of Physical Medicine and Rehabilitation

Kaufmann Medical Bldg. T: 412-648-6848  
Suite 201 F: 412-692-4410  
3471 Fifth Ave. Email: muninmc@upmc.edu  
Pittsburgh, PA 15213

A \$20 billion health care provider and insurer, Pittsburgh-based UPMC is inventing new models of patient-centered, cost-effective, accountable care. The largest nongovernmental employer in Pennsylvania, UPMC integrates 89,000 employees, 40 hospitals, 700 doctors' offices and outpatient sites, and a nearly 3.6 million-member Insurance Services Division, the largest medical insurer in western Pennsylvania. In the most recent fiscal year, UPMC contributed \$1.2 billion in benefits to its communities, including more care to the region's most vulnerable citizens than any other health care institution, and paid \$587 million in federal, state, and local taxes. Working in close collaboration with the University of Pittsburgh Schools of the Health Sciences, UPMC shares its clinical, managerial, and technological skills worldwide through its innovation and commercialization arm, UPMC Enterprises, and through UPMC International. *U.S. News & World Report* consistently ranks UPMC Presbyterian Shadyside on its annual Honor Roll of America's Best Hospitals and ranks UPMC Children's Hospital of Pittsburgh on its Honor Roll of America's Best Children's Hospitals. For more information, go to UPMC.com.

### ABOUT THE DEPARTMENT OF PHYSICAL MEDICINE AND REHABILITATION

- UPMC Presbyterian Shadyside is ranked by *U.S. News & World Report* as one of the nation's best hospitals for rehabilitation.
- The Department of Physical Medicine and Rehabilitation is consistently a top recipient of NIH funding for rehabilitation-related research.
- The Spinal Cord Injury Program at UPMC is one of only 14 in the country selected by the National Institute on Disability, Independent Living, and Rehabilitation Research (NIDILRR) as a model for other rehab providers.
- Department clinicians lead UPMC's rehabilitation network of more than 90 inpatient, outpatient, and long-term care facilities — one of the country's largest.