

UPMC Rehab Grand Rounds

University of Pittsburgh
School of Medicine
Department of Physical
Medicine and Rehabilitation
Pittsburgh, Pennsylvania

Address correspondence to:

Michael C. Munin, MD
Senior Editor and
Vice Chairman, Clinical
Program Development
Kaufmann Medical Bldg.
Suite 201
3471 Fifth Ave.
Pittsburgh, PA 15213
Telephone: 412-648-6848
Fax: 412-692-4410
E-mail: muninmc@upmc.edu

Tennis Elbow: Understanding a Physiatrist's Approach to Management

Megan Helen Cortazzo, MD, FAAPMR

Director, Physical Medicine and Rehabilitation Outpatient Clinics
Director, UPMC Mercy South Side Interventional Spine and Pain Program

David M. DeChellis, DO

Academic Chief Resident, Department of Physical Medicine and Rehabilitation

Clinical Vignette

KS is a 58-year-old female who presented to the UPMC outpatient clinic with the chief complaint of "elbow pain." She reported that her job aggravated her elbow symptoms since she was employed as an attendant at a local deli. On physical exam, cervical spine and shoulder were unremarkable. Inspection of the elbow did not reveal erythema, edema, temperature changes, or muscle atrophy. She had palpatory tenderness along the lateral epicondyle and pain with wrist extension. She was diagnosed with lateral epicondyle tendinopathy. Treatment included a steroid injection and a course of physical therapy. She returned three months later with some improvement in her symptoms. Because she was responding to treatment, she received another injection, continued physical therapy, and also underwent acupuncture treatment for her pain. However, one month later she presented to the clinic with an increase in previous lateral elbow pain. MRI was ordered and demonstrated an increased signal along the attachment site of the common extensor tendon to the lateral epicondyle. The bone marrow and joint space, as well as the triceps and biceps were unremarkable. Since she was symptomatic after four months of treatment, job duty modifications were ordered, and treatment continued with acupuncture and physical therapy. In two months, her condition improved to the point that she returned to work without any job restrictions. Almost immediately, she developed an increase in her pain. She was distressed by her inability to perform all job duties, and asked if anything else could be done for her.

www.UPMCPhysicianResources.com/Rehab or www.rehabmedicine.pitt.edu
For consults and referrals: 1-800-544-2500

Defining the Problem

Lateral epicondyle tendinopathy is a medical condition of the myotendinous junction of the wrist extensors at the lateral epicondyle, which was first described by Runge in 1873 as “schreibekrampfe,” which translates as “writer’s cramp.”¹ Commonly referred to as “lateral epicondylitis,” this condition was described as occurring in tennis players secondary to an improper backswing.² The official nomenclature of this entity was declared in 1883 when it appeared in an article by H.P. Majors in *The British Journal of Sports Medicine* titled “Lawn-Tennis Elbow.”³

The presenting symptoms for this condition typically involve the insidious onset of pain in the lateral aspect of the elbow, which may radiate distally into the forearm. Pain is often exacerbated with resisted wrist extension or repetitive wrist movements, especially with the elbow in full extension.⁴ Patients also may complain of weakness in grip strength occurring with attempts to grasp or carry objects with the affected upper limb. Edema or erythema at the lateral epicondyle is uncommon, and patients typically have transient symptom relief with activity modification or relative rest of the symptomatic limb.⁵

Epidemiology of Tennis Elbow

The layman term “tennis elbow” is misleading, as only approximately 5% of cases are associated with racquet sports.⁶ However, approximately 50% of tennis players will suffer from this condition at one point in their career, with a higher predilection for novice players.⁷ This condition typically presents in the dominant elbow of patients who are 45 to 54 years of age, without evidence for gender preponderance.⁸ The prevalence of lateral epicondyle tendinopathy is estimated to be between 1.3% to 2.8% in the general population,⁸ and up to 15% in high-risk occupations that includes butchers, manual laborers, and employees in the fish processing industry.⁹ High-risk occupations include ones that involve both a combination of repetitive and forceful movements of the arms. Smoking has been associated with lateral epicondyle tendinopathy.⁸

The natural history of this condition is favorable, with approximately 80% of patients obtaining clinical improvement at one year from onset.⁵

Pathophysiology Associated with Tennis Elbow

Tennis elbow may occur as the result of a single direct trauma to the lateral elbow, however, it is more commonly reported as an overuse syndrome of the wrist extensors.^{7,10} The extensor carpi radialis brevis (ECRB) is the most common muscle tendon involved with this condition, and was initially described by Cyriax in 1936¹¹ as the primary anatomic structure involved. However, in a third of cases the extensor digitorum communis also has been implicated as a source of dysfunction.^{4,12}

The nomenclature of this condition has frequently been considered a misnomer secondary to the actual pathophysiology. The suffix “itis” in lateral epicondylitis implies an inflammatory condition associated with the extensor tendons of the lateral epicondyle. Early studies by Nirschl et al showed fibroblastic invasion and vascular granulation of the ECRB, which he termed “angiofibroblastic hyperplasia.”¹³ Further investigation into the histologic characteristics revealed collagen disorganization, mucoid degeneration, and lack of inflammatory cells.^{4,13,14} Microdialysis studies of the ECRB in patients affected with tennis elbow failed to show an increase in the inflammatory mediator prostaglandin E2 compared to control subjects.¹⁵ Since active inflammation has not been proven, the terms “tendinopathy” and “tendinosis” are now the preferred terminology.^{4,10,16}

Predisposing factors may include repetitive microtrauma to the common extensor tendon due to repetitive eccentric and concentric motion, in combination with poor vascularization of the proximal ECRB undersurface.¹⁷

Pain is often the primary subjective complaint in patients with tennis elbow. The source of pain symptoms may be related to the release of neuropeptides, such as substance P and calcitonine gene-related peptides, from primary sensory nerves causing vasodilatation, plasma extravasation, and

hypersensitivity. Recent studies have shown evidence of immunoreactivity to substance P and the calcitonin gene-related peptide of sensory fibers within a subpopulation of blood vessels at the proximal tendon insertion of the ECRB.^{16,18} Immunoreactivity to glutamate, a well-known modulator of pain in the central nervous system, also has been observed in the ECRB tendons in patients with tennis elbow.¹⁹

TABLE 1: Differential Diagnosis for Lateral Epicondyle Tendinopathy

✓ Cervical radiculopathy
✓ Radial tunnel syndrome (posterior interosseous neuropathy)
✓ Supinator syndrome
✓ Dorsal antebrachial cutaneous nerve injury
✓ Radiocapitellar degeneration
✓ Proximal radial fracture
✓ Gouty arthritis
✓ Radiohumeral bursitis (Osgood's)
✓ Plica synovialis
✓ Osteochondritis dissecans of the capitellum
✓ Panner's disease (osteochondrosis of the capitellum)
✓ Radial collateral ligament pathology
✓ Proximal radial fracture
✓ Infection
✓ Referred pain from shoulder pathology

Examination and Diagnosis

The diagnosis of tennis elbow is essentially a clinical one. After obtaining a thorough history from the patient, the physical exam should start proximally with the evaluation of the cervical spine and shoulder girdle. When evaluating the cervical spine, emphasis should be placed on excluding a radiculopathy associated with the C6 and C7 nerve roots. Shoulder instability and mechanical dysfunction also should be tested, as pathology in this region may refer pain or place inappropriate stress on the lateral elbow distally.⁷ The examination should then proceed to the elbow. Limited active range of motion with wrist extension, as well as difficulty with maximal passive wrist flexion, may be noted secondary to pain at the lateral elbow. Palpation of the lateral epicondyle is often painful, with maximal point tenderness located at the lateral epicondyle or within 2 to 5 mm anterior and distal to it.²⁰ Tenderness at the supracondylar ridge may indicate the involvement of the extensor radialis carpi longus as well.²¹ Point tenderness palpated 3 to 4 cm distal to the lateral epicondyle, or at the edge of the supinator, should make the clinician suspicious of an etiology other than tennis elbow, such as radial tunnel syndrome.²²

Provocation maneuvers also are used by most clinicians in the attempt to induce concordant pain. The tennis elbow test, also referred to as Cozen's test, is considered positive if pain occurs at the lateral epicondyle of a fully extended elbow with resisted wrist extension.²⁰ Another provocation maneuver, originally described to assess for radial tunnel syndrome, is the Maudsley's test.²² Since then, it has been used by clinicians in detecting tennis elbow. This test is considered positive if pain is elicited at the lateral epicondyle of a fully extended elbow with resisted extension of the ipsilateral middle digit.¹² Although both of these provocative maneuvers are used regularly by clinicians, there is little evidence supporting their sensitivity and specificity.²⁰

Diagnostic Studies

Imaging is not routinely indicated, however is obtained when lateral epicondyle tendinopathy becomes refractory, or the clinician is suspicious that another medical condition may be the source of the patient's presenting symptoms.¹⁰ Plain radiographs of the elbow are typically negative and offer little diagnostic value for tennis elbow. Calcification along the lateral epicondyle is the most common finding associated with this condition.²³ Magnetic resonance imaging (MRI) and diagnostic ultrasonography also may be performed in selected cases to verify the suspected diagnosis, assess the degree of tendonopathy present, and identify any coexisting abnormalities.¹⁰ MRI has superior sensitivity compared to diagnostic ultrasonography, and produces imaging features that correlate well with histologic and surgical findings.^{10,14} Despite this, ultrasound (*see Figure 1*) still remains useful in the evaluation of lateral epicondyle tendinopathy with a sensitivity and specificity as high as 80% and 50% respectively.¹⁰

Electrodiagnostic studies also may be used when the clinician suspects that the patient's symptoms may

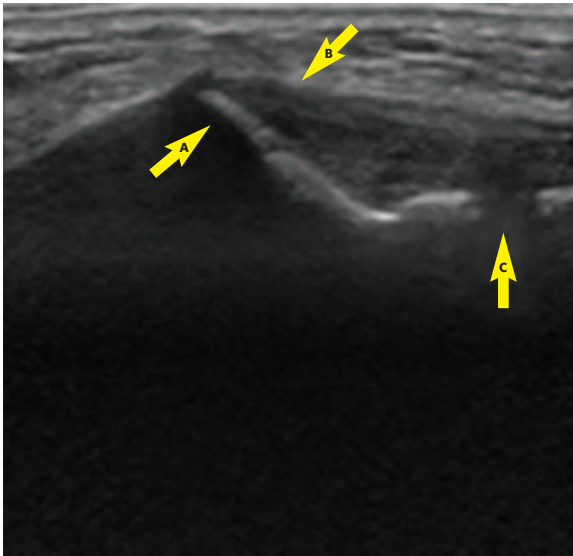


Figure 1: A. Lateral epicondyle B. Extensor attachment (note hypochoic structure) C. Joint line

be complicated by, or stemming from, a neurological source apart from tennis elbow. Testing in this scenario will help to exclude cervical radiculopathy affecting motor fibers and screen for focal neuropathies that can mimic the condition, such as posterior interosseous neuropathy.

Management of Tennis Elbow

Treatment typically incorporates nonsteroidal anti-inflammatory drugs (NSAIDs) or ice, as well as ergonomic advice and modification of exacerbating activities. However, there is poor evidence supporting the use of NSAIDs or ice for this condition.^{24,25}

Stretching, as well as strengthening, the wrist extensors using eccentric muscle training is often prescribed due to its theorized ability to reduce strain placed on the wrist extensors through inducing hypertrophy and increasing tensile strength of the myotendinous unit.⁵ However, this type of muscle training has not been shown to have significant advantage over concentric exercises or stretching alone.²⁶ The use of physical therapy in patients with lateral epicondyle tendinopathy can reduce time off from employment.²⁷

While many clinicians still consider localized corticosteroid injections a gold standard in the nonsurgical treatment of tennis elbow, there is little evidence in regard to efficacy. Injectable steroids may decrease the release of neuropeptides that have been theorized to be a source of pain in lateral epicondyle tendinopathy. One study has suggested that although superior initially, corticosteroid injections are significantly inferior in long-term follow-up to physical therapy and a wait-and-see approach.²⁸ The recurrence of symptoms after corticosteroid injection in long-term follow-up is quite high, and may approach up to 50% to 60%.^{9,29} Topical nitroglycerin is another modality that has been used to treat this condition. It is theorized that it may help to modulate tissue healing through enhancing the production of collagen by fibroblasts. Studies have shown conflicting data regarding the effects of topical nitroglycerin when compared to physical therapy alone.⁶

Many other treatment modalities have been used with the goal to alleviate symptoms and improve overall function in tennis elbow. Examples of such modalities include orthotic counterforce bracing, acupuncture, extracorporeal shock wave therapy, sclerotherapy, phonophoresis, iontophoresis, laser light therapy, and low-intensity ultrasound. Conflicting evidence exists regarding the benefits of these modalities.^{5,16,30} Another relatively new treatment proposed to improve symptoms is botulinum toxin injections. Theorized to reduce stress at the extensor myotendinous junction via partial paralysis, the initial limited evidence does not strongly support use in lateral epicondyle tendinopathy.³¹

Surgery is a treatment that is frequently reserved for refractory cases of tennis elbow. While open, percutaneous, and arthroscopic surgeries have all been described as approaches to this condition, little evidence is available to determine which surgical technique has superior benefit in overall outcome. Despite this fact, it is estimated that roughly 80% of patients have a successful outcome regardless of surgical technique used.³²

Although a large amount of anecdotal success has been reported, there is poor consensus supporting standardized treatment based on the scientific literature. The analysis of randomized clinical trials for the treatment of lateral epicondylitis frequently reveals significant methodology flaws, and there is a low level of evidence for current interventions.³³

New Treatment: Autologous Platelet-Rich Plasma

In the search for better treatment of tennis elbow, platelet-rich plasma (PRP) has gained popularity with musculoskeletal medicine physicians. Although highly debated, PRP, by its strictest definition, is an autologous sample of blood with a concentration of platelets above the physiologic baseline. The concept behind its use in nonsurgical musculoskeletal medicine is to inject areas of soft tissue pathology via percutaneous injection in order to facilitate tissue healing. This healing is theorized

to occur secondary to the PRP's ability to promote recruitment, proliferation, and differentiation of cells involved in tissue regeneration.^{34,35}

In order for platelets to influence tissue healing, activation is first required. This occurs through an external source, at which time platelets alter their morphological structure in a process known as degranulation. Some clinicians choose to activate the PRP prior to injection using a variety of sources, while others allow platelets to become activated in vivo through the interaction with type I collagen.³⁶ During this process platelets release up to 95% of their presynthesized growth factors and bioactive molecules from granules within the first hour after activation. These growth factors and molecules then induce advantageous changes within the healing cascade.^{34,35}

In regards to PRP in the treatment of tennis elbow, early anecdotal and case study reports have been encouraging. A small cohort study by Mirsha et al in 2006 showed an improvement of pain and overall function in patients treated with PRP compared to controls.³⁷ A more recent randomized controlled study by Peerbooms et al compared local PRP injection to local corticosteroid injection in patients with clinical evidence of chronic tennis elbow refractory to prior treatments.³⁷ Fifty-one patients were randomized to receive PRP injection, while 49 patients were randomized to receive corticosteroid injection. Successful treatment was defined as an improvement of 25% in a visual analog score (VAS) or Disability of the Arm, Shoulder, and Hand (DASH) Outcome Measure score without a reintervention after one year. Data showed significant differences between treatment groups. Specifically, 73% of patients in the PRP group compared to 49% of patients in the corticosteroid group had successful outcomes in VAS score ($p < .001$), while 73% of patients in the PRP group compared to 51% of patients were successful in the DASH score ($p = .005$).³⁸

Whole blood (rather than just injecting platelets) has been used in recent years to treat lateral epicondyle tendinopathy based on theoretical benefits that include bringing endogenous cellular and humoral

mediators within blood to augment healing.²⁹ Kazemi showed a statistically significant difference in pain and overall function in favor of patients receiving whole blood injection into the tendon compared to localized corticosteroid injection at four and eight weeks.²⁹

Clinical Vignette Summary

We offered KS the treatment option of platelet rich plasma for her chronic lateral epicondyle tendinopathy. We discussed the theoretical benefits, as well as current literature-supported evidence, with the patient in detail. KS elected to have the procedure based on the refractory nature and duration of her symptoms.

Upon ultrasonographic evaluation of her lateral epicondyle (*see Figure 1*), it was evident that the common extensor tendon was hypoechoic, signifying chronic degenerative changes in the tendon. After informed consent was obtained, 60 milliliters of the patient's blood was withdrawn and placed into a centrifuge system. Then 3 ml of platelet rich plasma was extracted for injection after the area was cleansed in an aseptic fashion. The skin overlying the injection site at the lateral epicondyle was anesthetized. The PRP solution was not activated prior to injection in order to allow this to occur in vivo after contact with the collagen associated with the wrist extensor tendon. Using ultrasound guidance (*see Figure 2*),

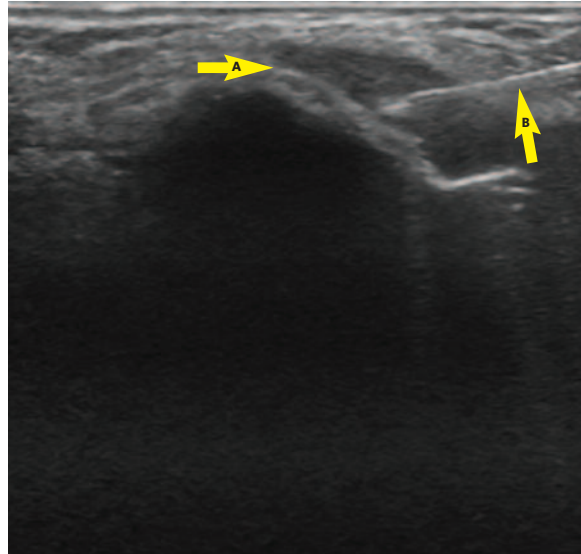


Figure 2: A. Lateral epicondyle and wrist extensor attachment B. Needle

the needle was advanced towards the proximal attachment of the common extensor tendon, as well as the hypoechoic regions. A total of 1.5 ml of platelet rich plasma was injected after percutaneous tenotomy was performed. KS stated that the injection was uncomfortable. At follow-up eight weeks after her treatment, the patient reported complete resolution of her symptoms and was working full time at her deli in an unrestricted fashion.

References

1. Runge F. Zur Genese und Behandlung des Schreiberkrampfes. *Berliner Klin Wochenschr* 1873;10: 245-48
2. Morris H, Riders sprain, *Lancet*, No. 557, 1882.
3. Major HP. Lawn-tennis elbow. *BMJ* 1883; 2:557.
4. Kraushaar B et al. Tendinosis of the elbow (tennis elbow): clinical features and findings of histological, immunohistochemical, and electron microscopy studies. *J Bone Joint Surg* 1999. 81-A(2); 259-79.
5. Calfee R et al. Management of lateral epicondylitis current concepts. *J Am Acad Orthop Surg* 2008;16:19-29.
6. Paoloni JA et al. Randomized, double-blind, placebo-controlled clinical trial of a new topical glyceryl trinitrate patch for chronic lateral epicondylitis. *Br J Sports Med* 2009: 299-302.
7. LaBan MM et al. Occult Periarthrosis of the Shoulder: A Possible Progenitor of Tennis Elbow. *Am J Phys Med Rehabil* 2005; 84(11): 895-98.
8. Shiri et al. Prevalence and determinants of lateral and medial epicondylitis: a population study. *Am J Epidemiol* 2006; 164 (11): 1065-74.
9. Bisset L et al. Mobilisation with movement and exercise, corticosteroid injection, or wait and see for tennis elbow: randomised trial. *BMJ* 2006; 333(7575): 939
10. Walz DM et al. Epicondylitis: Pathogenesis, Imaging, and Treatment. *Radiographics* 2010; 30: 167-184.
11. Cyriax JH. The pathology and treatment of tennis elbow. *J Bone Joint Surg* 1936;18: 921-40.
12. Fairbank et al. The role of the extensor digitorum communis muscle in lateral epicondylitis. *J Hand Surg Br* 2002; 27(5): 405-09.
13. Nirschl et al. Tennis elbow. The surgical treatment of lateral epicondylitis. *J Bone Joint Surg* 1979; 61:832-39.
14. Potter H et al. Lateral Epicondylitis: Correlation of MR imaging, surgical, and histopathologic findings. *Radiology* 1995;196: 43-46.
15. Alfredson H et al. In vivo investigation of ECRB tendons with microdialysis techniques: no sign of inflammation but high amounts of glutamate in tennis elbow. *Acta Orthop Scand* 2000; 71: 475-79.
16. De Smedt T. et al. Lateral epicondylitis in tennis: update on aetiology, biomechanics and treatment. *Br J Sports Med* 2007;41 (11): 816-19.
17. Schneeberger AG. Arterial vascularization of the proximal extensor carpi radialis brevis tendon. *Clin Orthop Relat Res* 2002: 239-44.
18. Ljung B et al. Substance P and calcitonin gene-related peptide expression at the extensor carpi radialis brevis muscle origin: implications for etiology of tennis elbow. *J Orthop Res* 1999; 17(4): 554-59.
19. Alfredson H et al. Chronic tendon pain: no signs of chemical inflammation but high concentrations of the neurotransmitter glutamate. Implications for Treatment? *Curr Drug Targets* 2002; 3: 43-6.
20. Malanga, GA and Nadler S. *Musculoskeletal Physical Examination: an Evidence-based Approach*. Philadelphia, PA: Elsevier Mosby, 2006. Print.
21. Plancher et al. Medial and lateral epicondylitis in the athlete. *Clin Sports Med* 1996;15: 283-304.
22. Roles NC et al. Radial tunnel syndrome: resistant tennis elbow as a nerve entrapment. *J Bone Joint Surg* 1972; 54B: 499-08.
23. Pomerance et al. Radiographic analysis of lateral epicondylitis. *J Shoulder Elbow Surg* 2002; 11(2): 156- 7.
24. Manias P et al. A controlled clinical pilot trial to study the effectiveness of ice as a supplement to the exercise programme for the management of lateral elbow tendinopathy. *Br J Sports Med* 2006; 40(1): 81-5.
25. Hay EM et al. Pragmatic randomised controlled trial of local corticosteroid injection and naproxen for treatment of lateral epicondylitis of elbow in primary care. *BMJ* 1999; 319(7215): 964-8.
26. Martinez-Silvestrini et al. Chronic lateral epicondylitis: Comparative effectiveness of a home exercise program including stretching alone versus stretching supplemented with eccentric or concentric strengthening. *J Hand Ther* 2005; 18: 411-19.
27. Solveborn SA et al. Radial epicondylalgia ("tennis elbow"): treatment with stretching or forearm band. A prospective study with long-term follow-up including range-of-motion measurements. *Scand J Med Sci Sports* 1997; 7: 229-37.
28. Smidt et al. Corticosteroid injections, physiotherapy, or a wait-and-see policy for lateral epicondylitis: a randomized controlled trial. *Lancet* 2002; 359 (9307): 657-62.
29. Kazemi et al. Autologous blood versus corticosteroid local injection in the short-term treatment of lateral elbow tendinopathy: a randomized clinical trial of efficacy. *Am J Phys Med Rehabil* 2010; 89(8): 660-67.
30. Fink et al. Acupuncture in chronic epicondylitis: a randomized controlled trial. *Rheumatology* 2002; 41 (2): 205-09.
31. Lin Y-C et al. Comparison Between Botulinum Toxin and Corticosteroid Injection in the Treatment of Acute and Subacute Tennis Elbow. *Am J Phys Med Rehabil* 2010; 89(8): 653-59.
32. Lo et al. Surgical treatment of lateral epicondylitis: a systematic review. *Clin Orthop Relat Res* 2007; 463: 98-106.
33. Cowan et al. Quality of prospective controlled randomized trials. Analysis of trials of treatment for lateral epicondylitis as an example. *J Bone Joint Surg* 2007; 89-A: 1693-99.
34. Marx RE et al. Platelet-rich plasma: Evidence to support its use. *J Oral Maxillofac Surg* 2004;62(4): 489-96.
35. Engerbretsen et al. IOC consensus paper on the use of platelet-rich plasma in sports medicine. *Br J Sports Med* 2010; 44(15):1072-81
36. Fufa D et al. Activation of platelet-rich plasma using soluble type I collagen. *J Oral Maxillofac Surg* 2008;66(4): 684-90.
37. Mirsha et al. Treatment of chronic elbow tendinosis with buffered platelet-rich plasma. *Am J Sports Med* 2006; 34 (11): 1774-78.
38. Peerbooms et al. Positive effect on an autologous platelet concentrate in lateral epicondylitis in a double-blind randomized control trial: platelet-rich plasma versus corticosteroid injection with a one-year follow-up. *Am J Sports Med* 2010; 38(2): 255-62.

No-Fee CME

UPMC is proud to be a resource for physicians across the country and around the world. Our commitment to CME is demonstrated here by offering CME credit free of charge for *Rehab Grand Rounds*. To receive CME credit for this piece, follow these easy steps:

1. Go to <https://cme.hs.pitt.edu>.
2. If you're a first-time user, you will need to create an account by going to "Create Account" on the right-hand side of the screen. Returning users will enter an e-mail address and password after clicking on "Login."
3. Once logged into the system, you can browse modules by selecting the UPMC Department of Physical Medicine and Rehabilitation-Grand Rounds folder then scrolling down to PMR Spring 2011.
4. After selecting a module, you can read about the module through the "Content Header" and then either click "Next Step" or use the "Step by Step" box.
5. The "Step by Step" box will guide you through the educational portion, quiz, evaluation, and certificate steps.
6. Please allow one business day for credit transcript. To print or view your transcripts, visit <https://ccehs.upmc.com>. On the left side of the page, click "Credit Transcripts."



The University of Pittsburgh School of Medicine is accredited by the Accreditation Council for Continuing Medical Education (ACCME) to provide continuing medical education for physicians. The University of Pittsburgh School of Medicine designates this educational activity for a maximum of 1.0 AMA PRA Category 1 Credits™. Each physician should only claim credit commensurate with the extent of their participation in the activity. Other health care professionals are awarded (0.1) continuing education units (CEU) which are equivalent to 1.0 contact hours.

UPMC Department of Physical Medicine and Rehabilitation

- UPMC is ranked by *U.S. News & World Report* as one of the top hospitals in the country for rehabilitation.
- The Department of Physical Medicine and Rehabilitation is a top recipient for NIH funding for rehabilitation-related research.
- The Spinal Cord Injury Program at UPMC is one of only 14 in the country selected by the National Institute on Disability and Rehabilitation Research as a model for other rehab providers.
- Department clinicians lead UPMC's rehabilitation network of more than 70 inpatient, outpatient, and long-term care facilities — one of the country's largest.

UPMC

To learn more about how UPMC is transforming physical medicine and rehabilitation, go to www.UPMCPhysicianResources.com/Rehab or www.rehabmedicine.pitt.edu.

UPMC is an \$8 billion global health enterprise with almost 50,000 employees headquartered in Pittsburgh, Pa., and is transforming health care by integrating 20 hospitals, 400 doctors' offices and outpatient sites, a health insurance services division, and international and commercial services. Affiliated with the University of Pittsburgh Schools of the Health Sciences, UPMC is redefining health care by using innovative science, technology, and medicine to invent new models of accountable, cost-efficient, and patient-centered care. For more information on how UPMC is taking medicine from where it is to where it needs to be, go to UPMC.com.

UPMC is an equal opportunity employer. UPMC policy prohibits discrimination or harassment on the basis of race, color, religion, ancestry, national origin, age, sex, genetics, sexual orientation, marital status, familial status, disability, veteran status, or any other legally protected group status. Further, UPMC will continue to support and promote equal employment opportunity, human dignity, and racial, ethnic, and cultural diversity. This policy applies to admissions, employment, and access to and treatment in UPMC programs and activities. This commitment is made by UPMC in accordance with federal, state, and/or local laws and regulations.